

CERVICAL LYMPHADENOPATHY IN IBADAN, NIGERIA

KO Aramide^{1*}, MA Ajani¹ and CA Okolo²

1. Department of Histopathology, Babcock University, Ilishan-Remo, Nigeria.
2. Department of Pathology, University College Hospital Ibadan, Nigeria.

Correspondence:

Dr. K.O. Aramide

Department of Histopathology,
Babcock University,
Ilishan- Remo,
Ogun State, Nigeria.
E-mail: kolawolearamide@yahoo.com
Tel: +2348033597001

ABSTRACT

Aim: To determine the pattern and causes of lymph node enlargement of cervical region in Ibadan, Nigeria.

Materials and Methods: A 10-year (2003-2012) retrospective study was conducted on all head and neck lymph node biopsies received at the Department of Pathology, University College Hospital, Ibadan, Nigeria.

Results: A total of 101 lymph node biopsies of cervical region were received within this period of study. 59.4% cases were seen in Males. Second decade of life has the highest number of cases (22.8%) followed by 3rd decade (17.8%). The common cause of cervical lymphadenopathy include non-specific hyperplasia, tumour metastasis and Non Hodgkin's lymphoma seen in 27 (26.7%), 22 (21.8%) and 20 (19.8%) respectively. Granulomatous and Hodgkin's Lymphoma constitute 17 (16.8%) and 11 (10.9%) respectively. The granulomatous causes were all due to tuberculosis. A single case of Rosai-Dorfman disease was seen in a male in the 3rd decade of life.

Conclusion: This study shows that metastatic tumours, Hodgkins lymphoma and Non Hodgkins lymphoma constituting 52.4% of all cases of cervical lymphadenopathy are common in this environment therefore highlighting the need for early and proper evaluation of patients.

Keywords: Lymph node, Cervical region, Metastatic, Lymphomas, Ibadan

INTRODUCTION

Lymphadenopathy is a common clinical finding that may be localized, limited or generalized. The enlargement of a lymph node, due to primary disease or secondary cause, is of concern to both patients and clinicians, particularly, if the underlying pathology is a malignant disease.¹ Cervical lymphadenopathy is the commonest form of peripheral lymphadenopathy.² It has many causes, including benign, infectious and malignant conditions. The evaluation of cervical lymphadenopathy is a common diagnostic challenge facing clinicians.²

Many literature reported that tuberculosis is the most common cause of cervical lymphadenopathy in sub-Saharan Africa, accounting for 17-66% of cases.¹⁻⁶ However a previous study from University College Hospital, Ibadan by Thomas et al. reported that 37% are due to normal or non-specific reactive changes, 27.7% showed granulomatous inflammation and 35.5% showed malignancy, lymphoid or metastatic tumours.⁶ Tuberculosis was the single most common granulomatous inflammatory condition constituting 94.5% of the granulomatous inflammatory lesions.⁶ Tuberculosis was also the commonest cause of lymph

node enlargement in childhood (0-14 years) while malignant condition was the commonest above forty-five years of age.⁶

There are many studies on peripheral lymphadenopathy in Nigeria but not many on cervical lymphadenopathy as an entity which makes having preformed information on likely causes of cervical lymphadenopathy difficult to clinicians.

The aim of this study was to provide a recent update on causes of cervical lymphadenopathy and its common causes in this environment to help clinicians in management of cases of cervical lymphadenopathy

MATERIALS AND METHODS

All cases of lymph node biopsies of cervical region from the files and records of Department of Pathology, University College Hospital, Ibadan, Nigeria from 1st January, 2003 to 31st December, 2012 were reviewed.

The age, sex and clinical diagnosis were retrieved. The relevant slides were retrieved from the archives of the

Department of Pathology. Where necessary, new slides were made from formalin fixed, paraffin embedded blocks and stained with haematoxylin and eosin stain. Special stains including Ziehl-Neelsen to demonstrate acid-fast bacilli were used where indicated. Immunohistochemistry was also performed when indicated using the following antibodies: CD 5, CD 10, CD 20, CD 23, CD 15, CD 30, Bcl 2, CD 45, AE1/AE3, S100, NSE, and Vimentin.

The age ≤ 14 years was classified as children and > 14 years as an adult.

The data obtained was analysed using the Statistical Package for Social Sciences, version 20 (SPSS 20) using the student's t and F tests for continuous variables, while categorical variables were analysed using the chi-squared test, with the level of statistical significance set at $p < 0.05$.

Neoplastic diseases constitute 53 (52.5%) of cases with metastatic tumour making up 41.5% and lymphomas constituting 58.5% of the neoplastic cases. The Non Hodgkin's lymphomas (NHL) are commoner in males with a male to female ratio of 1.5:1 and the Diffuse large B cell type constitute 70% of cases. The Hodgkin's lymphoma (HL) has a slightly higher male preponderance with a male to female ratio of 1.2:1 with the Nodular sclerosis variant constituting 63.6% of cases with 4 out of the 7 cases occurring in male. (Table 2). The peak age incidence of NHL is 2nd decade while the HL has two peaks of 1st and 3rd decades of life.

Metastatic causes are more in males than females with a ratio of 1.2:1 with an increasing frequency from 2nd decade of life and no case seen in the 1st decade, the commonest cause seen is metastatic adenocarcinoma

Table 1: Age group distribution of causes of cervical lymphadenopathy

Age Group	NHL	HD	MET	GRA	NSH	OTHERS	Total (%)
0-10	5	3	0	1	7	0	16 (15.8)
11-20	6	2	3	5	6	1	23 (22.8)
21-30	0	3	4	6	3	2	18 (17.8)
31-40	2	0	3	2	2	1	10 (9.9)
41-50	0	1	4	2	2	0	9 (8.9)
51-60	2	1	1	1	2	0	7 (6.9)
61-70	2	1	4	0	5	0	12 (11.9)
>70	3	0	3	0	0	0	6 (5.9)
Total	20	11	22	17	27	4	101

All the cervical lymph node biopsies processed with satisfactory and adequate tissue section within the period of review were included in this study.

All the cases with incomplete data (such as no age, sex) in their request cards and poorly processed biopsies were excluded from this study.

RESULTS

Out of all the 429 lymph node biopsies received during this period 101 (23.5%) were from the cervical region with 60 (59.4%) cases in male and 41(40.6%) cases in female and a male to female ratio of 1.4:1. (Figure 1). Seventy-four (73.3%) are adults and 27 (26.7%) are children. (Table 1).

Non specific hyperplasia (NSH) constituted 27 (26.7%) cases with follicular hyperplasia making up majority of the cases with sinus histiocytosis, parafollicular hyperplasia and dermatopathic lymphadenopathy having two cases each. NSH was more in males with a male to female ratio of 2.9:1 and also of higher frequency in the 1st and 2nd decades of life.

Table 2: Specific distribution of causes of cervical lymphadenopathy

CAUSE	NUMBER
Follicular hyperplasia	21
Sinus histiocytosis	2
Parafollicular Hyperplasia	2
Dermatopathic lymphadenopathy	2
Granulomatous	17
Carcinoma	15
Sarcoma	1
Invasive Ductal carcinoma	6
DLBCL	4
LBL	5
SLL	5
BL	5
FL	1
NSCHL	7
LRCHL	-
MCCHL	4
Rosai Dorfman Disease	1
Lymphoepithelial cyst	1
Normal	2
TOTAL	101

Table 3: Showing Age distribution of cervical lymphadenopathy

Age	0-10	11-20	21-30	31-40	41-50	51-60	61-70	>70
Number	16	23	18	10	9	7	12	6

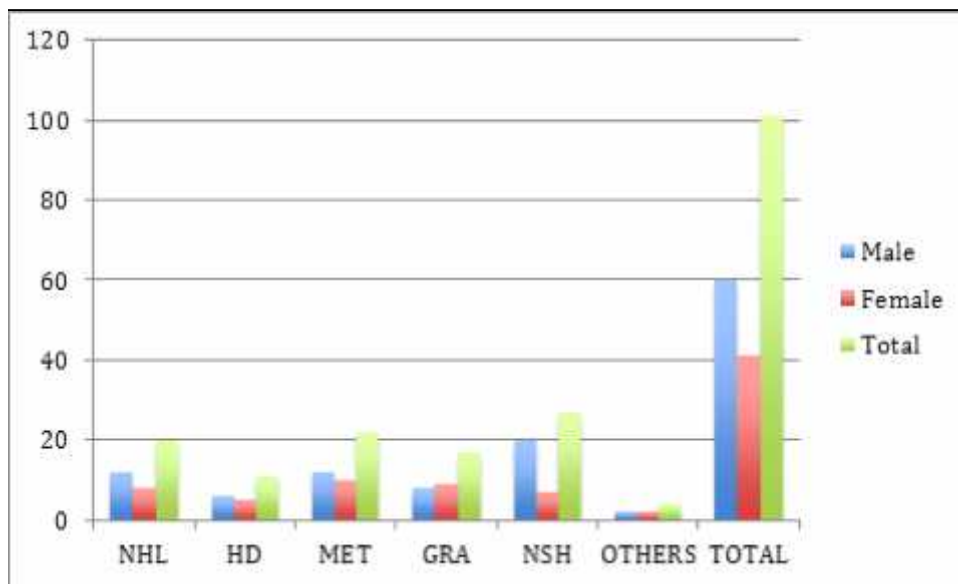


Figure 1: Sex Distribution of Causes of Cervical lymphadenopathy

KEY:

- NHL – Non-Hodgkin Lymphoma
- HD – Hodgkin Disease
- MET – Metastasis
- GRA – Granulomatous
- NSH – Non Specific Hyperplasia
- DLBCL – Diffuse large B cell lymphoma
- LBL – Lymphoblastic lymphoma
- SLL – Small lymphocytic lymphoma
- BL – Burkitt lymphoma
- FL – Follicular lymphoma
- NSCHL – Nodular sclerosis classical Hodgkin lymphoma
- LRCHL – Lymphocyte Rich classical Hodgkin lymphoma
- MCCHL – Mixed cellularity classical Hodgkin lymphoma

(NOS) which is more in males followed by metastatic invasive ductal carcinoma of the breast, all in females. Twenty one cases are seen in adult and a single case in a child.

Granulomatous causes constituted 17 (16.8%) of cases, with tuberculosis as the only cause in all the cases, the peak age was in the 2nd and 3rd decades with a decreasing frequency after then and no case seen beyond the 6th decade and none also in the 1st decade of life. 15(88.2%) cases were seen in adults and 2(11.8%) in children. There is a slight female preponderance of male to female ratio of 1:1.1.

DISCUSSION

Lymphadenopathy is one of the most common problems in clinical practice and offers an important diagnostic clue to the aetiology of the underlying condition.⁷ The cause of lymphadenopathy often cannot be ascertained on clinical grounds alone and lymph node biopsy with resultant histopathological examination serves as the gold standard for diagnosis. Tuberculosis has been reported by several authors as the predominant cause of lymph node enlargement in adults in the tropics.^{2,6} however in this study cervical lymphadenopathy resulting from malignant conditions (Non-Hodgkin's lymphoma, Hodgkin's lymphoma and metastasis) account for 52.5 %. This is similar to the findings in the series from South Africa and Saudi Arabia that reported 46% and 42% respectively.^{8,9} Lymphomas made up 30.7% of cases with Non Hodgkin's lymphomas accounting for 20% and Hodgkin's lymphoma 11%.

While Hodgkin's lymphoma occurred predominantly in young adult males with paucity of cases above the age of 41 years, there was a relatively wider spread of cases of non-Hodgkin's lymphoma with ages ranging from 5 -70 years which is similar to the findings of Olu-eddo *et.al.*² Also in the series from Malawi the commonest cause in both adults and children were malignant conditions constituting 35% and 26%

respectively.¹⁰ In agreement with most previous reports from Nigeria and other parts of the tropics metastatic carcinoma (21.7%) was the predominant cause of chronic cervical lymphadenopathy in patients above 40 years with a striking rarity in children.^{9,11,12}

Metastatic carcinoma constituted 41.5% of all malignant cases with only one case seen in a child, which is similar to the findings in series from Nigeria and other parts of Africa.^{2,3,7,11}

Non-specific hyperplasia, which constituted 26.7% of all cases, is a well-documented cause of cervical lymphadenopathy in the tropics with similar findings.^{6,11,12} which has been documented as a common cause of lymph node enlargement in the tropics and rates ranging from 15-22% have been observed in adults in previous Nigerian and other African series.^{6,11,12} Higher figures of 20.6-41.0% have however been observed in children.^{10,11}

Non Specific hyperplasia was seen more in males and also more in adults which is similar to the findings in Benin by Olu- Eddo *et al.*²

This study shows a low occurrence of granulomatous inflammation as a cause of cervical lymphadenopathy this is probably due to a great number of them being diagnosed used aspiration cytology and followed by commencement of therapy and thereby reducing the need for surgical biopsies this is corroborated by V Koo *et al* that discovered that a significant number of cases of FNAC diagnosed granulomatous lymphadenitis have an identifiable underlying causal pathology and then suggested that FNAC combined with clinical correlation is useful as a first line investigation¹³.

CONCLUSION

Cervical lymphadenopathy is a common clinical presentation and that it is important to always find out the primary cause of it for specific intervention due to the observation that a significant percentage is due to malignant causes.

Conflicts Interest

No conflicts of interest.

Authors Contributions

Conception and design: KO Aramide

Data analysis and interpretation: KO Aramide, MA Ajani, CA Okolo

Drafting or critical revision for important intellectual content: KO Aramide, MA Ajani, CA Okolo

Approval of the version to be published: KO Aramide, MA Ajani, CA Okolo

REFERENCES

1. **Abba AA**, Khalil MZ. Clinical approach to Lymphadenopathy. *Ann Nigerian Med* 2012; 6:11-17.
2. **Olu-eddo AN**, Omoti CE. Diagnostic evaluation of primary cervical adenopathies in a developing country. *Pan Afr Med J.* 2011; 10:52.
3. **Nkhoma W**, Wirima J. Review of Lymph Node Biopsies: Medical Ward, Kamuzu Central Hospital, 1985-1988. *Malawi Med J.* 1991 Jan; 7(1): 25-27.
4. **Getachew A**, Demissie M, Gemechu T. Pattern of histopathologic diagnosis of lymph node biopsies in a teaching hospital in Addis Ababa, 1981-1990 G.C. *Ethiop Med J.* 1999 Apr; 37(2): 121-127.
5. **Ojo BA**, Buhari MO, Malami SA, Abdulrahman MB. Surgical lymph node biopsies in university of Ilorin teaching hospital, Ilorin, Nigeria. *Niger Postgrad Med J.* 2005 Dec; 12(4): 299-304.
6. **Thomas JO**, Ladipo JK, Yawe T. Histopathology of lymphadenopathy in a tropical country. *East Afr Med J.* 1995 Nov; 72 (11): 703-705
7. Anunobi CC, Banjo AA, Abdulkareem FB, *et al.* Review of the histopathologic pattern of superficial lymph node diseases in Lagos, Niger *Postgrad Med J*, 2008; 15(4), 243-246
8. **Al-Sohaibani MO**. Cervical lymphadenopathy in the eastern province of Saudi Arabia. *East Afr Med J*, 1996 Aug; 73(8): 533-537
9. **Muthuphei MN**. Cervical lymphadenopathy at Ga-Rankuwa Hospital (South Africa): a histological review. *Cent Afr J Med.* 1998 Dec; 44(12): 311-312.
10. **Mabedi C**, Kendig C, Liomba G, *et.al.* Causes of cervical lymphadenopathy at Kamazu Central Hospital. *Malawi Medical journal* 26(1); 16-19
11. **Mandong BM**, Nwana EJC, Igun G, Dakum AN. Surgical lymph node biopsies in Jos University Teaching Hospital, Jos, Nigeria. *Nig J Surg Res.* 1999; 1 (2): 63-67
12. **Pindiga UH**, Dogo D, Yawe T. Histopathology of primary peripheral lymphadenopathy in North Eastern Nigeria. *Nig J Surg Res.* 1999; 1: 68-77
13. **V Koo**, TF Lioe, RAJ Spence. Fine needle aspiration cytology (FNAC) in the diagnosis of granulomatous lymphadenitis *Ulster Med J* 2006; 75 (1) 59-64